

[www.medscape.com](http://www.medscape.com)

## Examining the Fingernails When Evaluating Presenting Symptoms in Elderly Patients **CME/CE**

Complete author [affiliations and disclosures](#) are at the end of this activity.

---

**Release Date: March 26, 2008; Valid for credit through March 26, 2009**

### Target Audience

This activity is intended for primary care professionals who treat the elderly patient.

### Goal

The goal of this activity is to appropriately assess the fingernails of the elderly patient

### Learning Objectives

Upon completion of this activity, participants will be able to:

1. Visually examine the fingernails for abnormalities
2. Recognize specific fingernail abnormalities
3. Identify systemic conditions associated with fingernail abnormalities

### Credits Available

**Physicians** - maximum of 0.5 *AMA PRA Category 1 Credit(s)*<sup>™</sup> for physicians;

**Nurses** - 0.5 nursing contact hours (None of these credits is in the area of pharmacology)

All other healthcare professionals completing continuing education credit for this activity will be issued a certificate of participation.

Physicians should only claim credit commensurate with the extent of their participation in the activity.

### Accreditation Statements

#### For Physicians



Medscape, LLC is accredited by the Accreditation Council for Continuing Medical Education (ACCME) to provide continuing medical education for physicians.

Medscape, LLC designates this educational activity for a maximum of 0.5 **AMA PRA Category 1 Credit(s)**<sup>™</sup>. Physicians should only claim credit commensurate with the extent of their participation in the activity.

For questions regarding the content of this activity, contact the accredited provider for this CME/CE activity: [CME@medscape.net](mailto:CME@medscape.net). For technical assistance, contact [CME@webmd.net](mailto:CME@webmd.net).

## For Nurses

This Activity is sponsored by Medscape Continuing Education Provider Unit.

Medscape is an approved provider of continuing nursing education by the New York State Nurses Association, an accredited approver by the American Nurses Credentialing Center's Commission on Accreditation.

Awarded 0.5 contact hour(s) of continuing nursing education for RNs and APNs; none of these credits is in the area of pharmacology.

Provider Number: 6FDKKC-PRV-05

For questions regarding the content of this activity, contact the accredited provider for this CME/CE activity: [CME@medscape.net](mailto:CME@medscape.net). For technical assistance, contact [CME@webmd.net](mailto:CME@webmd.net).

## Instructions for Participation and Credit

There are no fees for participating in or receiving credit for this online educational activity. For information on applicability and acceptance of continuing education credit for this activity, please consult your professional licensing board.

This activity is designed to be completed within the time designated on the title page; physicians should claim only those credits that reflect the time actually spent in the activity. To successfully earn credit, participants must complete the activity online during the valid credit period that is noted on the title page.

Follow these steps to earn CME/CE credit\*:

1. Read the target audience, learning objectives, and author disclosures.
2. Study the educational content online or printed out.
3. Online, choose the best answer to each test question. To receive a certificate, you must receive a passing score as designated at the top of the test. Medscape encourages you to complete the Activity Evaluation to provide feedback for future programming.

You may now view or print the certificate from your CME/CE Tracker. You may print the certificate but you cannot alter it. Credits will be tallied in your CME/CE Tracker and archived for 6 years; at any point within this time period you can print out the tally as well as the certificates by accessing "Edit Your Profile" at the top of your Medscape homepage.

\*The credit that you receive is based on your user profile.

---

This activity is supported by funding from WebMD.



## Legal Disclaimer

The material presented here does not necessarily reflect the views of Medscape or companies that support educational programming on [www.medscape.com](http://www.medscape.com). These materials may discuss therapeutic products that have not been approved by the US Food and Drug Administration.

Copyright © 2008 Medscape.

---

## Contents of This CME/CE Activity

- [Examining the Fingernails When Evaluating Presenting Symptoms in Elderly Patients](#)

Mark E. Williams, MD

## Examining the Fingernails When Evaluating Presenting Symptoms in Elderly Patients

### Introduction

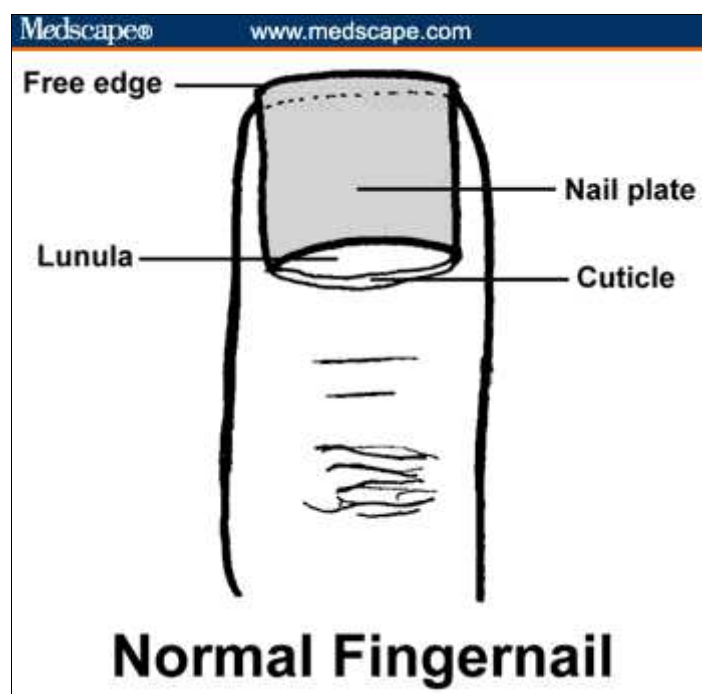
Human fingernails, located on the dorsal aspect of the terminal 40% of the distal phalanx of each finger, are complex structures involving 3 different layers:

- The nail plate (the nail). This is the keratinized structure, which grows throughout life;
- The nail bed (ventral matrix, sterile matrix). This is the vascular bed that is responsible for nail growth and support. It lies protected between the lunula (the "half moon" seen through the nail) and the hyponychium (the posterior part of the nail bed epithelium); and
- The eponychium (cuticle). The epidermal layer between the proximal nail fold and the dorsal aspect of the nail plate.

The primary purpose of the nail is protection. Abnormalities of the nail are often caused by skin disease and infection (most often fungal) but may also indicate more general medical conditions. This discussion does not address localized trauma or nail infections but offers examples of nail abnormalities that may occur with systemic disease.

Check to see whether the nails are normal by looking at the following (Figure 1):

- Softness and flexibility of free edge;
- Shape and color;
- Quality of paronychia tissue; and
- Growth rate (about 6 months from cuticle to free edge). Time of events can be estimated from location.



**Figure 1.** The normal nail.

## Examining the Nails

Elderly people carry the last 6 months of their medical record on the approximately 10 square centimeters of keratin comprising the fingernails. Examining the fingernails can help the clinician detect a number of general and specific factors, including the following:

- Overall vitality;
- Inner emotional state;
- Cerebral dominance;
- Occupations and hobbies;
- Medical history;
- Nutritional status;
- Cardiovascular function;
- Rheumatic conditions; and
- Dermatologic problems.

The patient's manicure can reveal state of health, nutritional status, past events, personality, occupation, and one's inner state. Systemic illness should show the nail changes in each of the nails on one hand. The thumb may reveal more extensive changes given its increased size.

It is useful to follow the following sequence when examining the nails:

- Check the nail shape;
- Examine the nail color;
- Survey processes around the nails;
- Compare hands; and
- Note skin conditions.

It is critical to examine the nails in adequate light. Gently rotate the nail in the light so that the reflection highlights all aspects of the nail. Notice the lunula, the pale crescent moonlike coloration at the base of the nail. Leukonychia stria and a pointed tent-like lunula suggest an excessive manicure and pushing on the cuticle. Paronychias suggest stress and poor attention to hygiene. This can reflect depression, dementia, or psychiatric illness.

## Nail Growth

Nail growth is continuous. It takes about 6 months for a fingernail in an elderly person to completely grow out. Cold temperature can slow growth rates but not to any clinically significant degree (pun intended). The middle finger nail grows the fastest, followed by the forefinger and ring finger. Aging slows the growth rate from approximately 3 months in childhood to 6 months in 70-year-olds. Nails in elderly people are also thicker than in younger people. Thin nails in a postmenopausal woman raise the possibility of metabolic bone disease. The nails of the dominant hand grow slightly more quickly than the nondominant nails, probably because minor trauma accelerates nail growth. Conversely, immobility slows the growth rate of fingernails. Understanding the growth rate is important because the time interval from a critical event can be estimated from the location of a nail lesion. For example, a white line appearing transversely halfway up the nail suggests an acute illness 3 months earlier. Regular observation will demonstrate its progression to the end of the nail edge.

## Nail Polish

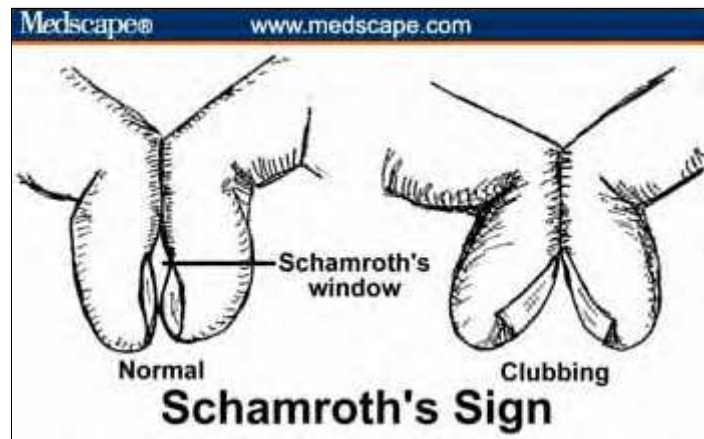
Distance from base and line of polish gives approximate date of application (nails grow 0.1 mm/day). Picking at polish reflects nervousness and agitation. Toenail polish suggests unusual flexibility or a friendly helper.

## Observing the Nail Shape and Surface

### Clubbed Fingernails

Clubbing involves a softening of the nail bed with the loss of normal Lovibond angle between the nail bed and the fold, an increase in the nail fold convexity, and a thickening of the end of the finger so it resembles a drumstick.

To determine whether nails are clubbed, have the patient place both forefinger nails together and look between them. If you can see a small diamond space between them (Schamroth's window) then the nails are *not* clubbed (Schamroth's sign) (Figure 2).

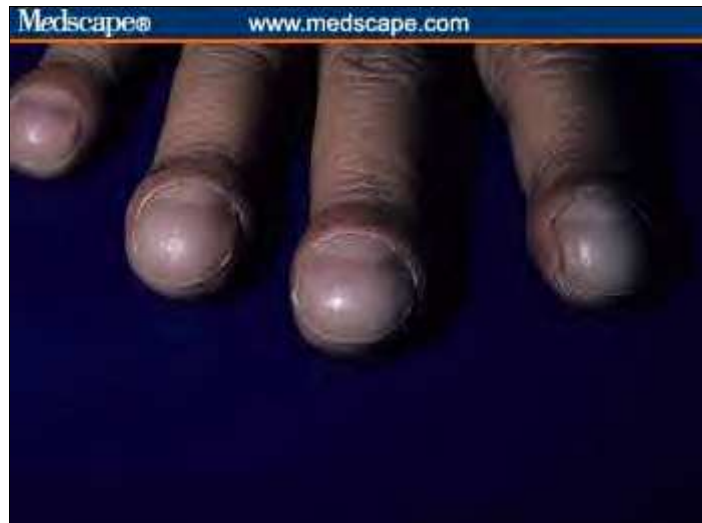

**Figure 2.** Schamroth's sign.

Causes of clubbing (not exhaustive) include the following (Figure 3):

- Pulmonary and cardiovascular causes (80%)
  - Lung cancer, pulmonic abscess, interstitial pulmonary fibrosis, sarcoidosis, beryllium poisoning, pulmonary arteriovenous fistula, subacute bacterial endocarditis, infected arterial grafts, aortic aneurysm
- Gastrointestinal causes (about 5%)
  - Inflammatory bowel disease, sprue, neoplasms (esophagus, liver, bowel)
- Hyperthyroidism (about 1%)

Note: Chronic obstructive pulmonary disease does not cause clubbing.

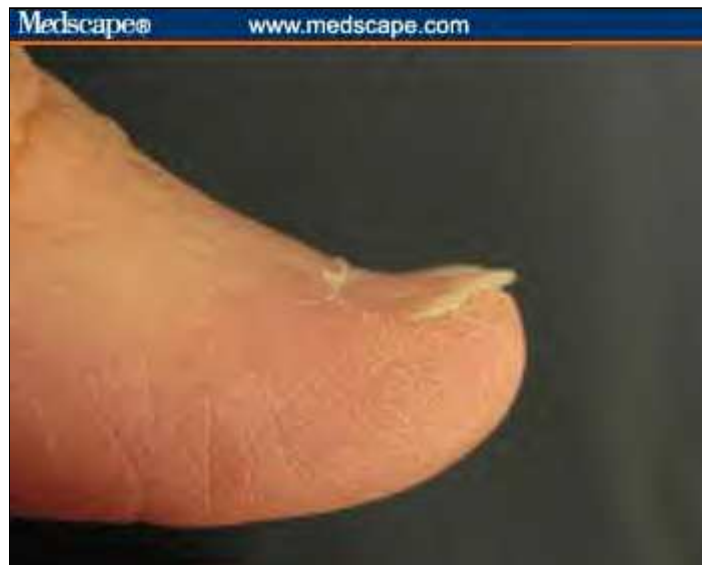

**Figure 3.** Example of clubbed fingernails.

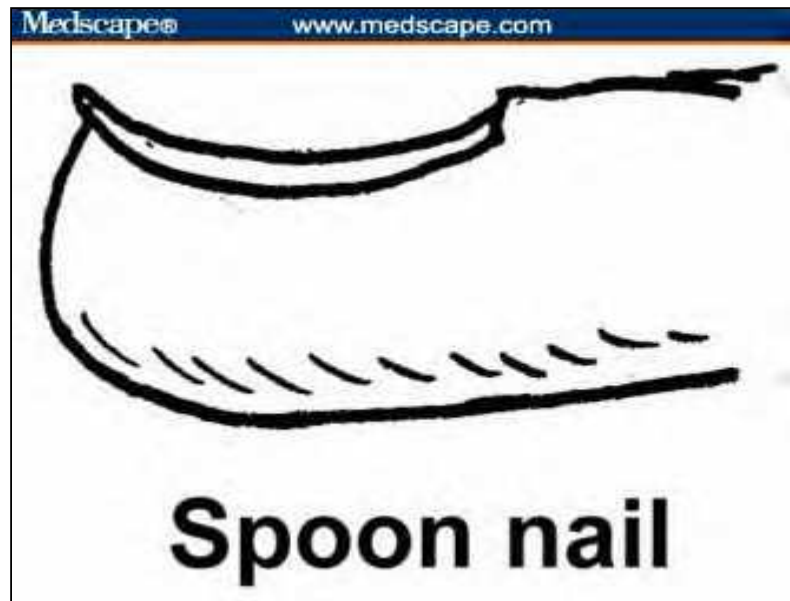
### Koilonychia

Koilonychia are spoon-shaped concave nails (Figures 4A, 4B). This occurs normally in children and usually resolves with aging. To determine whether a nail is spooned, perform the water drop test. Place a drop of water on the nail. If the drop does not slide off, then the nail is flattened from early spooning. An experienced clinician can look at the nail and perform a "mental" water drop test. Causes include the following:

- Iron deficiency;
- Diabetes mellitus;
- Protein deficiency, especially in sulfur-containing amino acids (cysteine or methionine);
- Exposure to petroleum-based solvents;
- Systemic lupus erythematosus; and
- Raynaud's disease.



**Figure 4A.** Spooned nail.



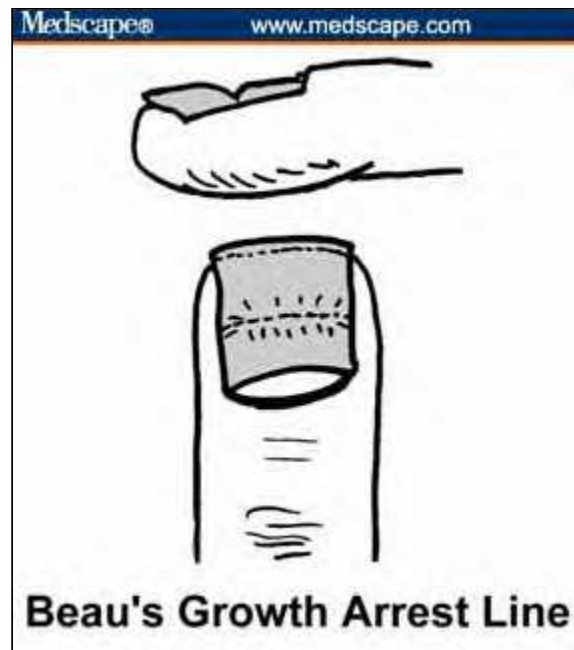**Figure 4B.** Spooned nail.

In 1846, Joseph Honoré Simon Beau described transverse lines in the substance of the nail as signs of previous acute illness. The lines look as if a little furrow had been plowed across the nail. Illnesses producing Beau's lines include the following:

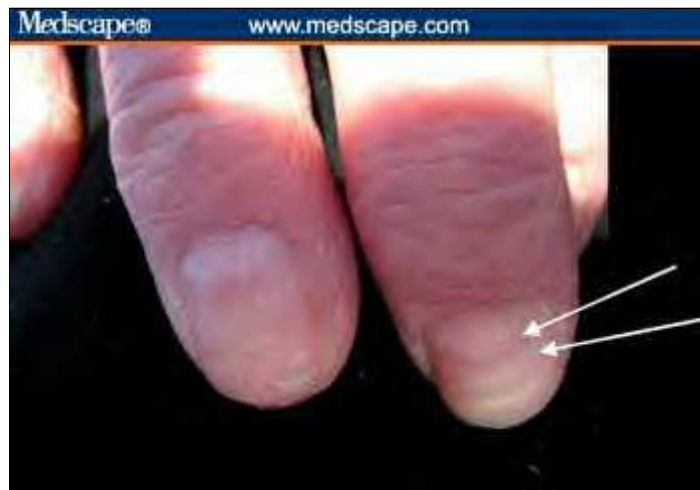- Severe infection;
- Myocardial infarction;
- Hypotension, shock;
- Hypocalcemia; and
- Surgery.

Intermittent doses of immunosuppressive therapy or chemotherapy can also produce Beau's lines. Severe zinc deficiency has also been proposed as a cause of Beau's lines.

By noting its location on the nail, the approximate date of the illness associated with it can be determined (Figures 5A, 5B). Moreover, the depth of the line provides a clue to the severity of the illness.



**Figure 5A.** The location of Beau's lines half way up the nail suggests illness 3 months ago.



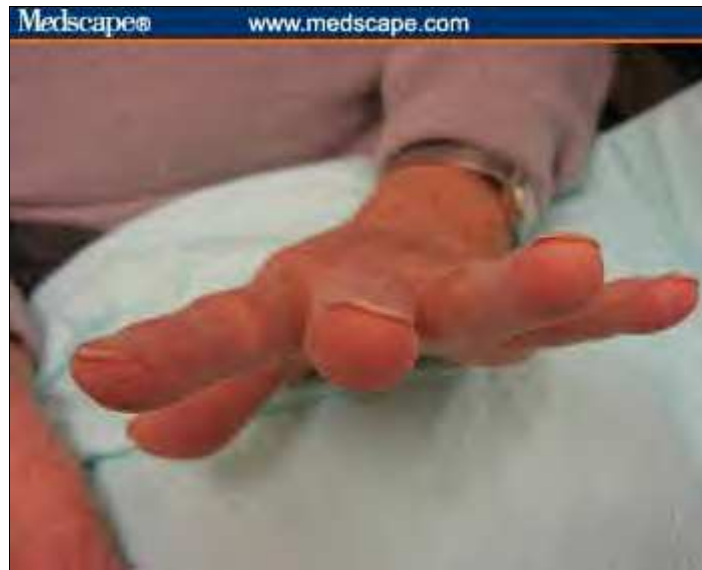**Figure 5B.** Two Beau's lines suggest illnesses about 2 months apart.

### Thin Brittle Nails

Thin, brittle nails can indicate the following (Figure 6):

- Metabolic bone disease (nail thinness is correlated with osteopenia);
- Thyroid disorder;
- Systemic amyloidosis (indicated by yellow waxy flaking); and
- Severe malnutrition.





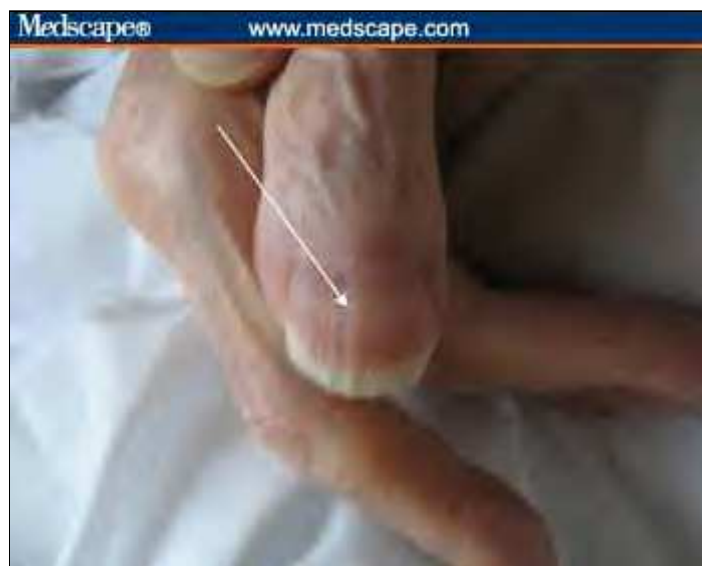**Figure 6.** Note the thin nails in this woman with severe osteopenia.

Onychorrhexis is the presence of longitudinal striations or ridges (Figure 7). It can simply be a sign of advanced age but it can also occur with the following:

- Rheumatoid arthritis;
- Peripheral vascular disease;
- Lichen planus; and
- Darier's disease (striations are red/white).

Central ridges can be caused by:

- Iron deficiency;
- Folic acid deficiency; and
- Protein deficiency.

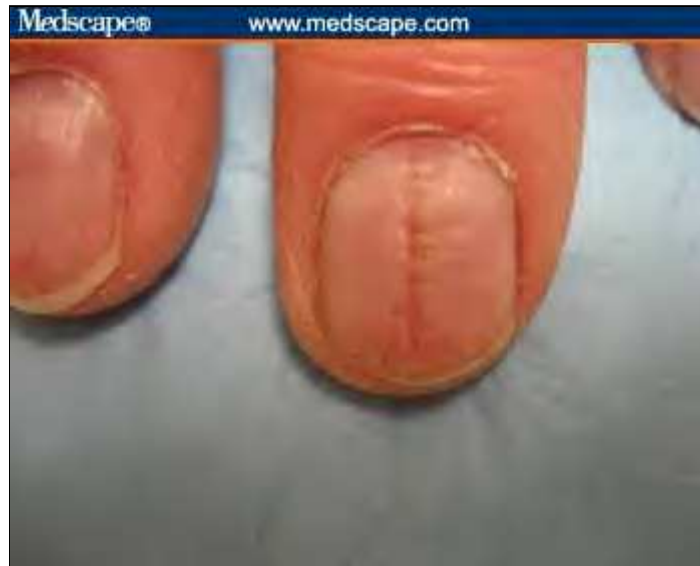

**Figure 7.** Example of a central nail ridge.

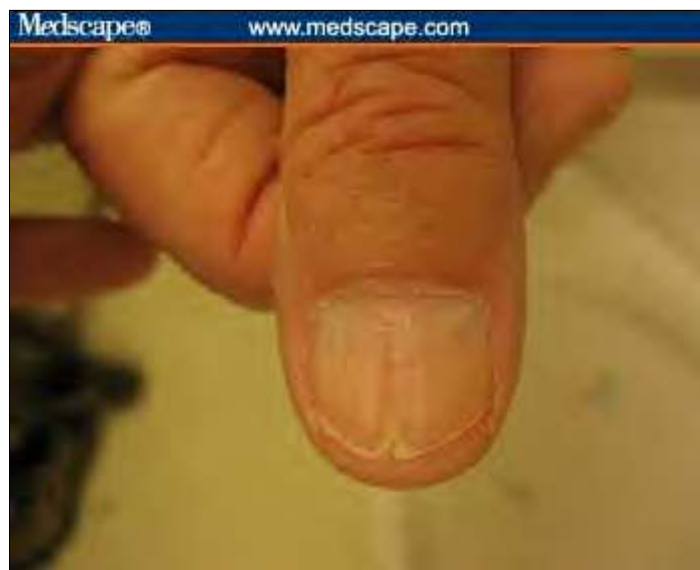### Central Nail Canal (Median Nail Dystrophy)

When a central nail canal is present, the cuticle is usually normal (Figure 8A). Central nail canal is associated with:

- Severe arterial disease ("Heller's fir tree deformity" -- a central canal with a fir tree appearance -- may occur with peripheral artery disease (Figure 8B);
- Severe malnutrition; and
- Repetitive trauma.



**Figure 8A.** Example of central nail canal.

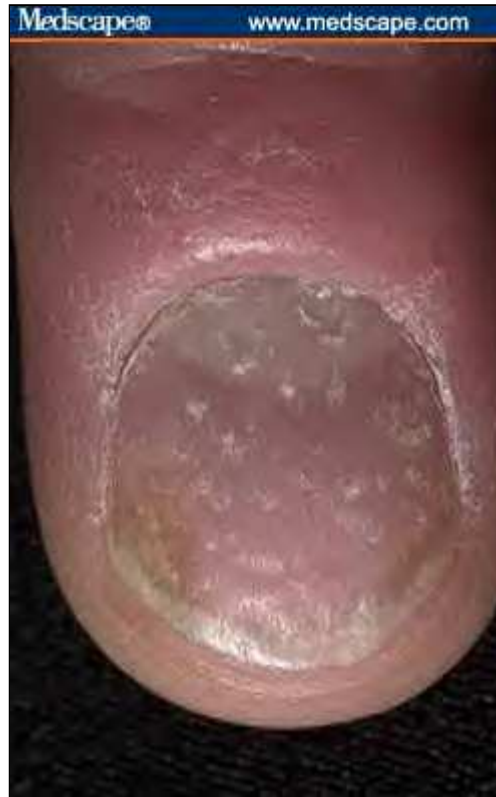

**Figure 8B.** Central nail canal with Heller's fir tree deformity.

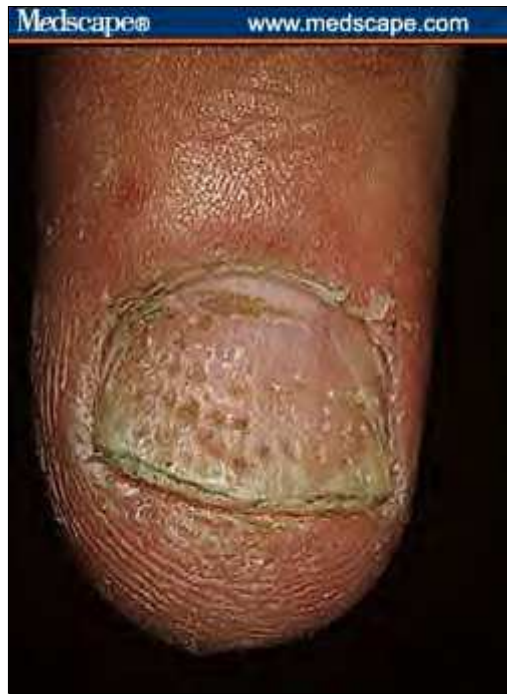### Nail Pitting

Nail pitting -- small punctate depressions -- are caused by nail matrix inflammation, which can be the result of:

- Psoriasis (random appearance of pits) (Figure 9);
- Alopecia areata (geometric rippled grid) (Figure 10);
- Eczema; and
- Lichen planus.



**Figure 9.** Indication of psoriasis.

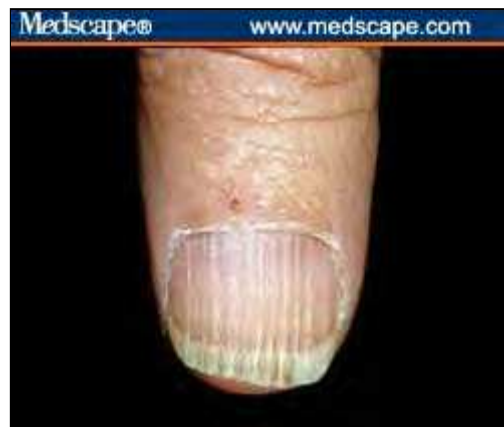

**Figure 10.** Indication of alopecia areata.

### **Nail Beading**

With nail beading, the beads seem to drip down the nail like wax (Figure 11). It is associated with endocrine conditions, including the following:

- Diabetes mellitus;
- Thyroid disorders;
- Addison's disease; and
- Vitamin B deficiency.

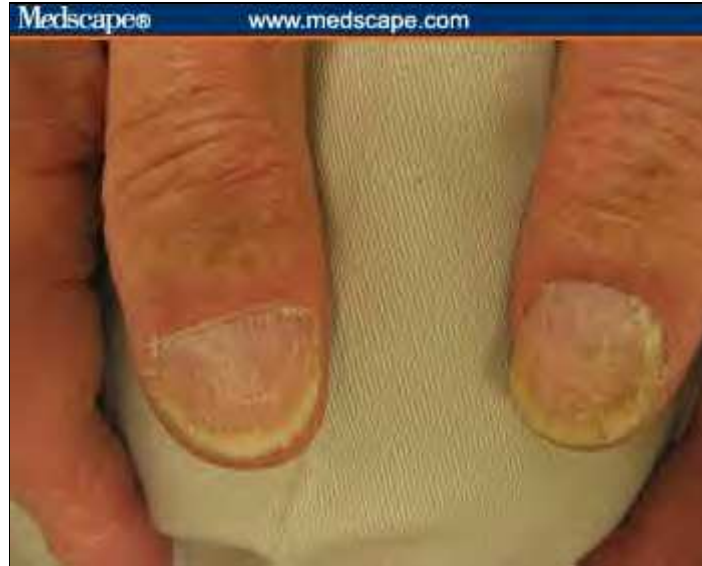

**Figure 11.** Nail beading.

### **Rough Nail Surface**

When nails look sandpapered and dull, consider (Figure 12):

- Autoimmune disease;
- Psoriasis;
- Chemical exposure; and
- Lichen planus.

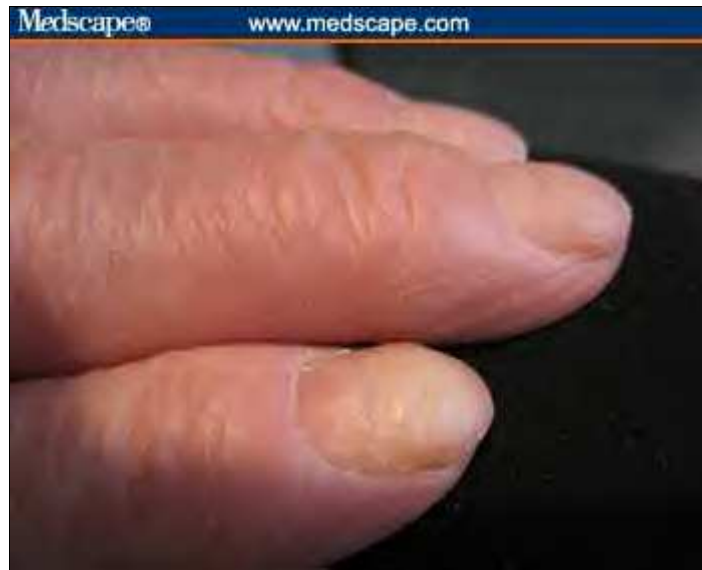

**Figure 12.** Example of a rough nail surface.

### **Nail Thickening**

Slow nail growth produces thickness (Figure 13). In such cases, the following should be considered:

- Onychomycosis;
- Chronic eczema;
- Peripheral vascular disease;
- Yellow nail syndrome; and
- Psoriasis.

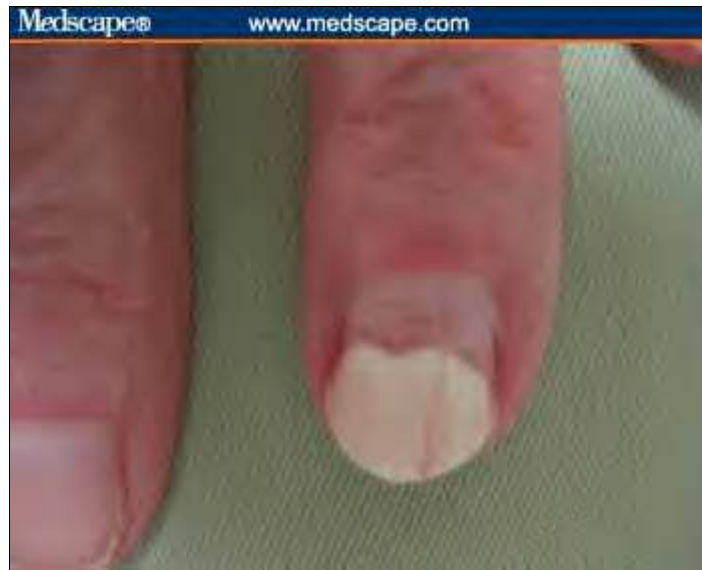

**Figure 13.** Example of a nail thickening.

### **Onycholysis**

Onycholysis is distal separation of the nail plate from the underlying nail bed (Figure 14). It is associated with the following:

- Thyrotoxicosis;
- Psoriasis;
- Trauma;
- Contact dermatitis;
- Tetracycline;
- Eczema;
- Toxic exposures (solvents);
- Blistering from autoimmune disease; and
- Porphyria cutanea tarda (onycholysis and skin blistering from sun exposure).

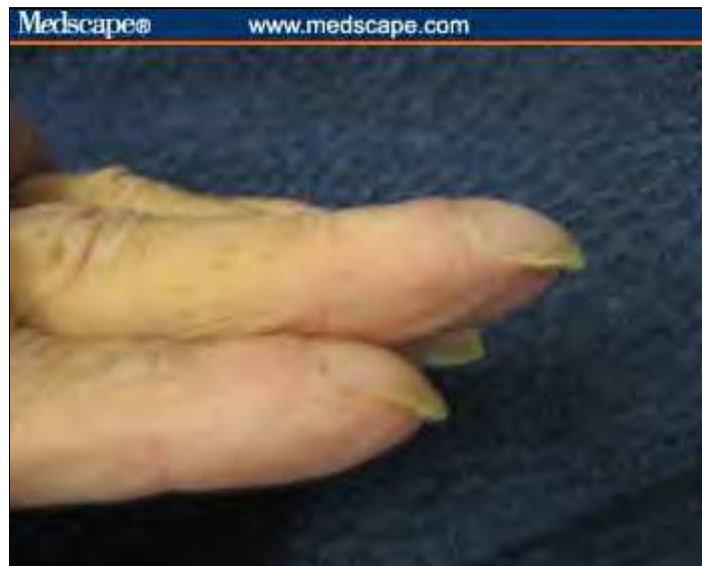

**Figure 14.** Traumatic onycholysis (involving only 1 nail).

### **Severe Nail Curvature (Beaked Nails)**

Curved or beaked nails are caused by resorption of distal digit (Figure 15). Consider the following:

- Hyperparathyroidism
- Renal failure
- Psoriasis
- Systemic sclerosis



**Figure 15.** Example of severe nail curvature.

### **Complete Nail Destruction**

Complete local nail destruction can be caused by local mechanisms, including trauma and paronychia. Generalized

conditions that might cause complete nail destruction include the following:

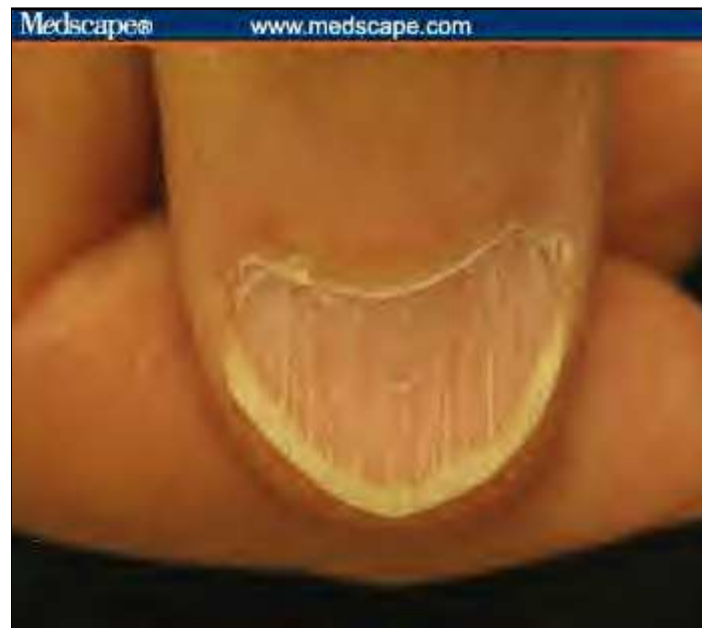- Toxic epidermal necrolysis;
- Chemotherapy;
- Bullous diseases; and
- Vasculitis.

## Observing Nail Color

### Abnormalities of the Lunula

If the lunula is absent, consider anemia or malnutrition (Figure 16). A pyramidal lunula might indicate excessive manicure or trauma (Figure 17). A pale blue lunula suggests diabetes mellitus. If the lunula has red discoloration, consider the following causes among others (Figure 18):

- Cardiovascular disease;
- Collagen vascular disease; and
- Hematologic malignancy.

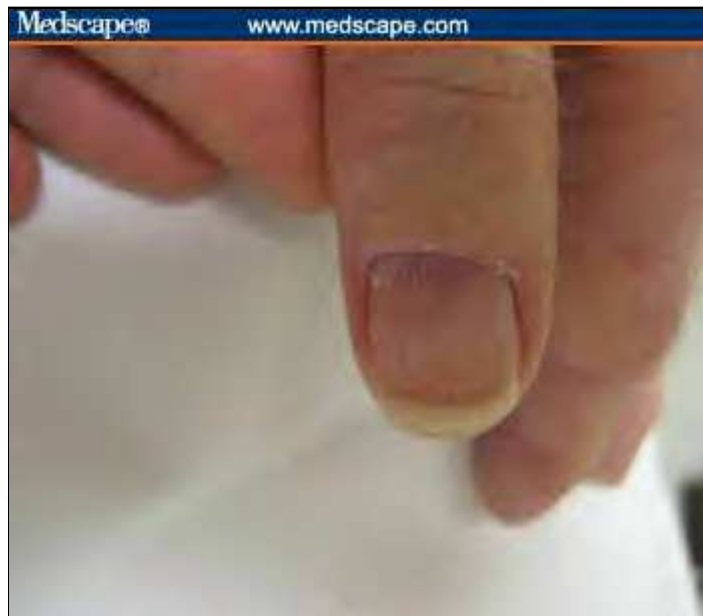

**Figure 16.** Absent lunula.





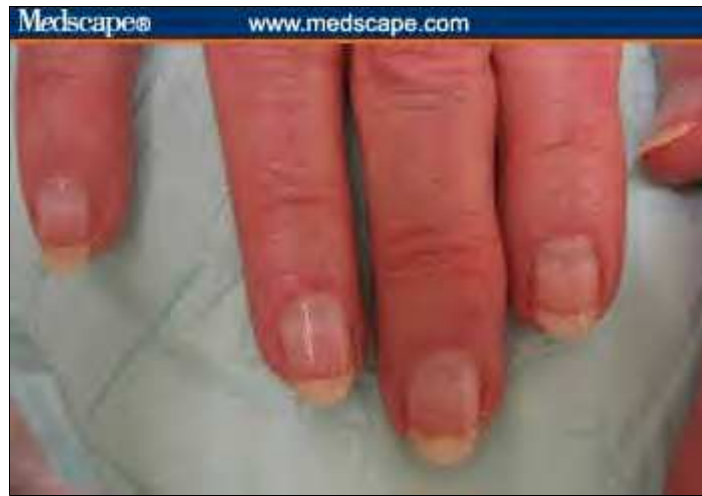**Figure 17.** Pyramidal lunula.



**Figure 18.** Lunula with red discoloration.

### **Transverse White Lines (Mee's lines)**

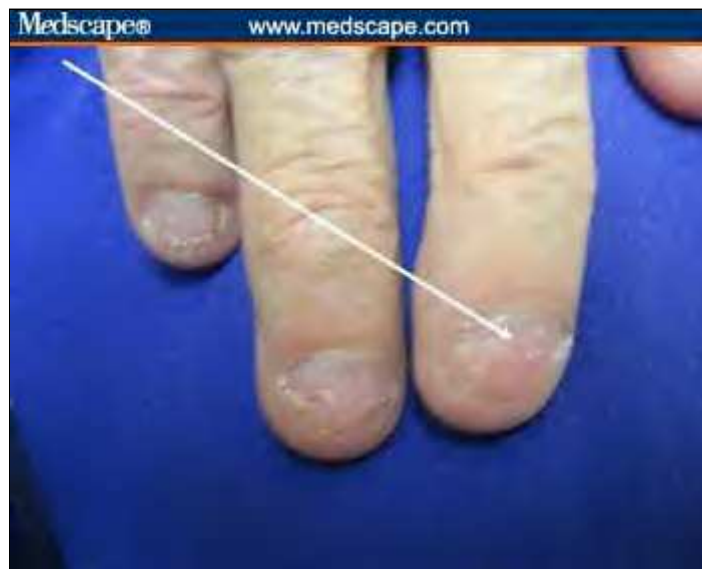Any acute illness can produce transverse milky white lines. In addition, they might be caused by heavy metal toxicity (classically arsenic) or chemotherapy. The time of event may be determined from the location of the lines on nail (Figure 19).



**Figure 19.** Note the Mee's line approximately one third of the way up the nail, suggesting a significant illness 2 months previously.

### Leukonychia Striae

Leukonychia striae are white splotches caused by minor trauma to the nail matrix (Figure 20). The timing can be determined by the location of the splotches on the nail.



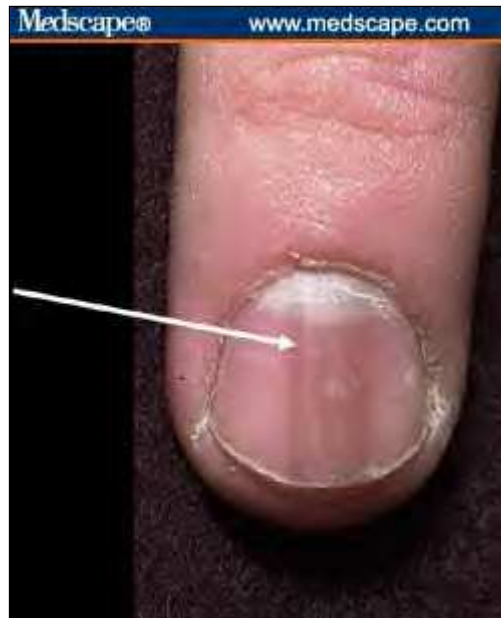**Figure 20.** Example of leukonychia striae. Note location of white splotches, which can indicate timing of the traumatic event.

### Longitudinal Brown Lines

Longitudinal brown lines form because of increased melanin produced by nail matrix melanocytes (Figure 21). They are associated with:

- Addison's disease;
- Nevus at the nail base;
- Breast cancer;

- Melanoma (check for periungal pigmentation); and
- Trauma.

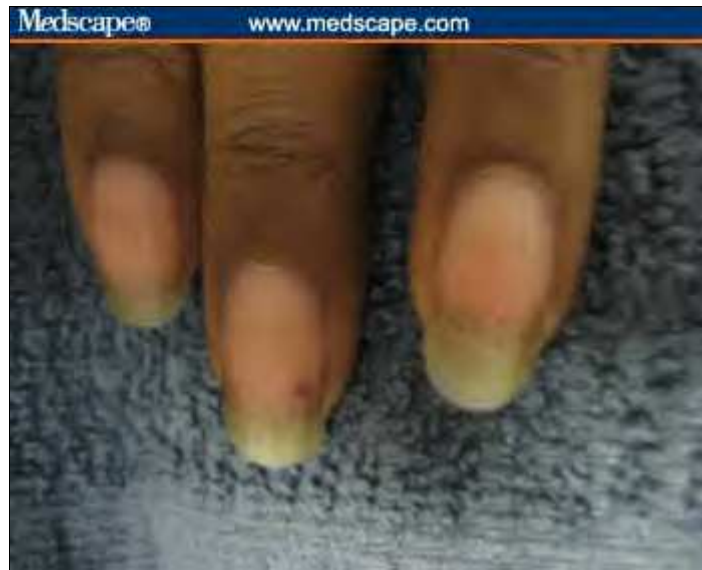

**Figure 21.** Longitudinal brown lines.

### **Splinter Hemorrhages**

Splinter hemorrhages are caused by hemorrhage of the distal capillary loop (Figure 22). Note the thickness of these areas. They are associated with the following:

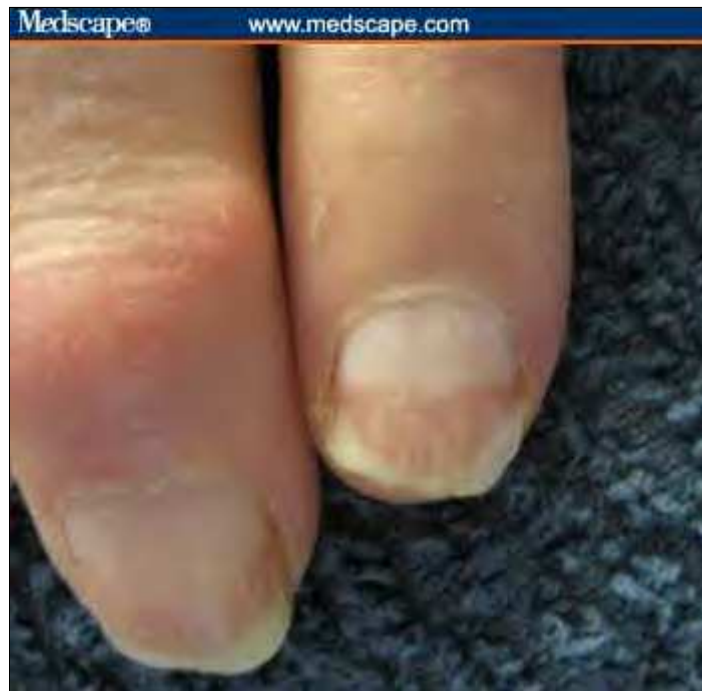- Subacute bacterial endocarditis;
- Systemic lupus erythematosus;
- Trichinosis;
- Pityriasis rubra pilaris;
- Psoriasis; and
- Renal failure.



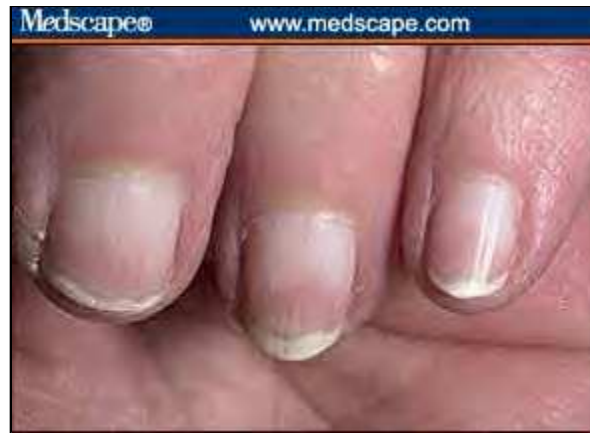**Figure 22.** Splinter hemorrhages tend to be fat.

### **Terry's Half and Half Nails**

With Terry's half and half nails, the proximal portion is white (edema and anemia) and the distal portion is dark. These nails imply either renal or liver disease (Figures 23A, 23B).



**Figure 23A.** This example of Terry's half and half nails suggests liver disease (no brown lines).



**Figure 23B.** Half and half nails imply renal disease when there is a brown band at the junction of the erythema and the free edge. Image courtesy of [www.dermnet.com](http://www.dermnet.com) Used with permission.

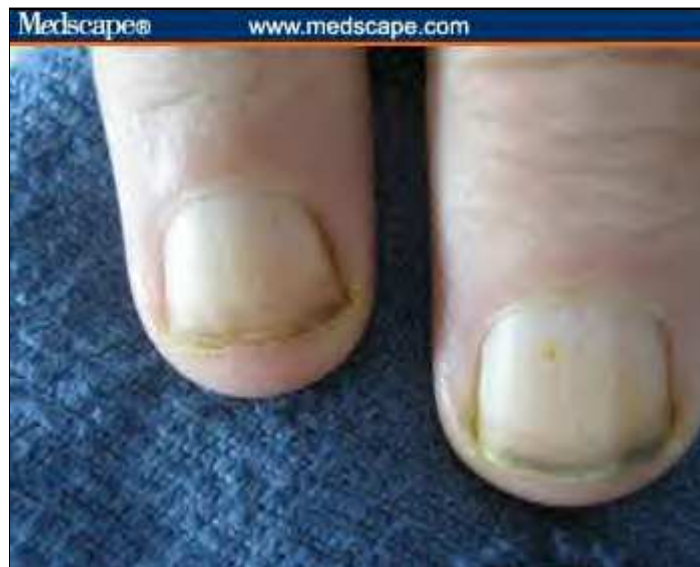### Generalized Discolorations of the Nail Plate

Nail discoloration is a useful method for identifying potential problems.

#### White Nails

White nails can be caused by anemia, edema, or vascular conditions (Figure 24). Consider the following:

- Anemia;
- Renal failure;
- Cirrhosis;
- Diabetes mellitus;
- Chemotherapy; and
- Hereditary (rare).

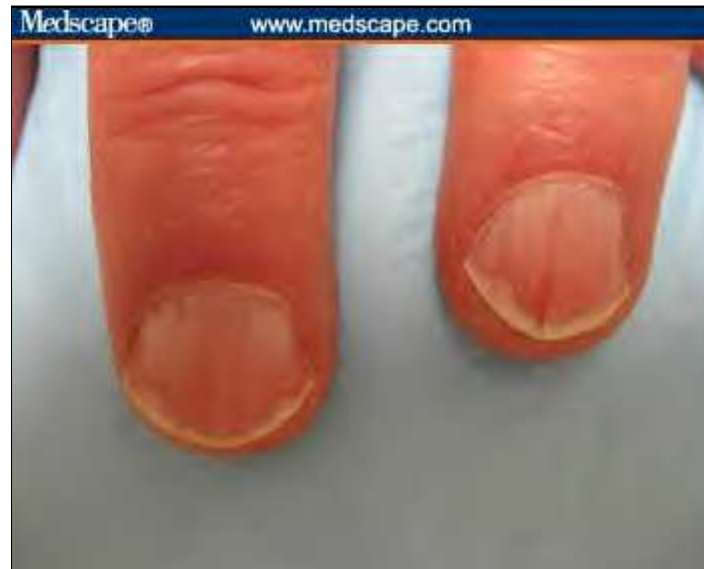

**Figure 24.** Example of white nails.

### **Pink or Red Nails**

With pink or red nail discoloration, the following should be considered (Figure 25):

- Polycythemia (dark);
- Systemic lupus erythematosus;
- Carbon monoxide (cherry red);
- Angioma; and
- Malnutrition.

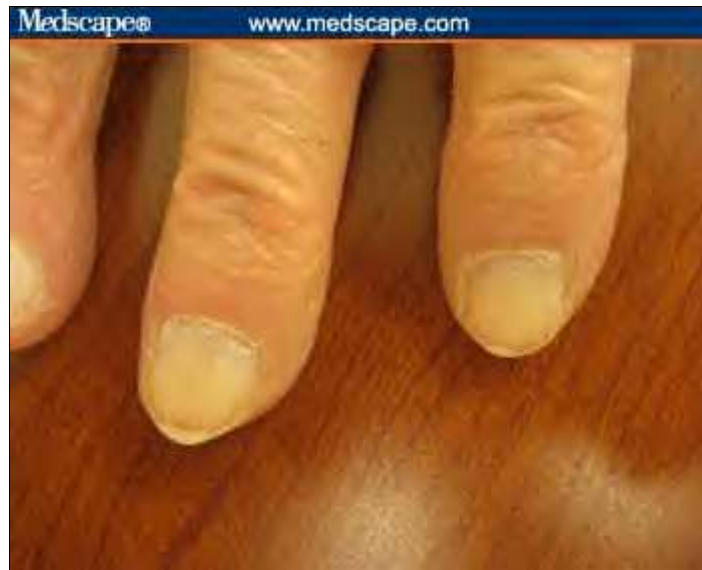

**Figure 25.** Example of pink and red nails.

### **Brown-Gray Nails**

Brown-gray nails may suggest the following (Figure 26):

- Cardiovascular disease;
- Diabetes mellitus;
- Vitamin B12 deficiency;
- Breast cancer;
- Malignant melanoma;
- Lichen planus;
- Syphilis; and
- Topical agents, including hair dyes, solvents for false nails, varnish, and formaldehyde (among many others)



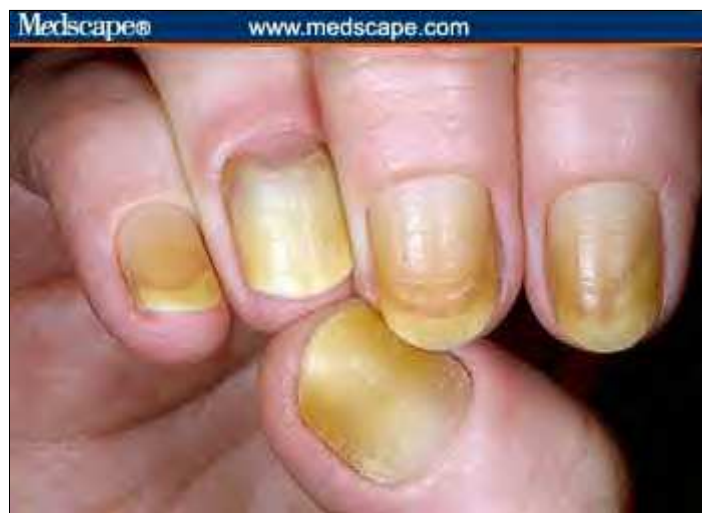**Figure 26.** Example of brown-gray nails.

### **Yellow Nails**

Yellow nails suggest the following (Figure 27):

- Diabetes mellitus;
- Amyloidosis;
- Median/ulnar nerve injury;
- Thermal injury; and
- Jaundice.

Consider yellow nail syndrome if a patient has lymphedema and bronchiectasis.



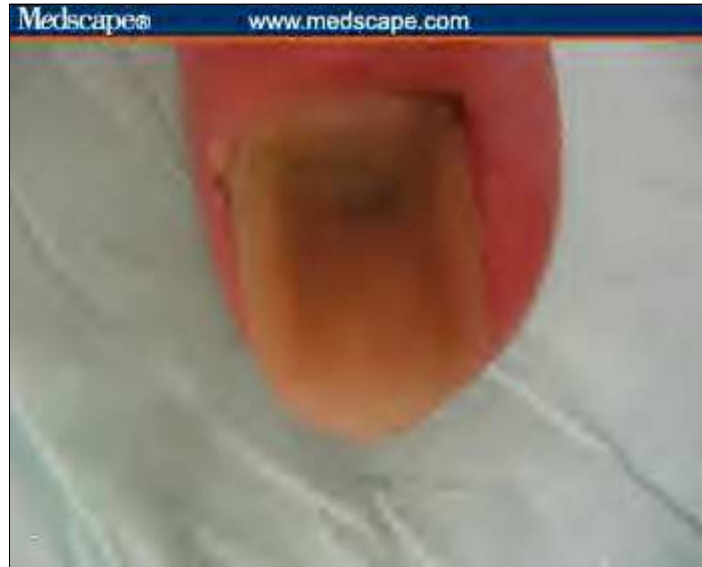**Figure 27.** Example of yellow nails. Image courtesy of [www.dermnet.com](http://www.dermnet.com) Used with permission.

### **Green or Black Nails**



Green or black nails indicate the following (Figure 28):

- Topical preparations, including chlorophyll derivations, methyl green, and silver nitrate (among others);
- Chronic *Pseudomonas* spp infection; and
- Trauma.

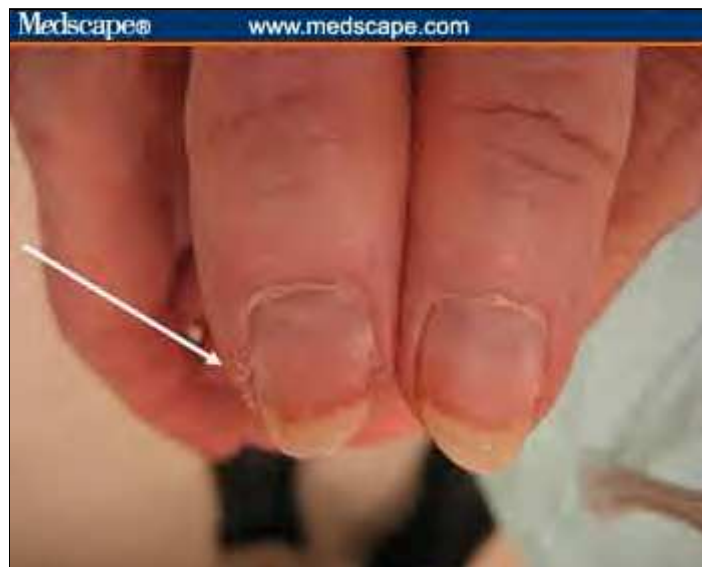

**Figure 28.** Example of black nails.

## Processes Around the Nail

### Paronychial Inflammation

Paronychia is associated with separation of the seal between the proximal nail fold and the nail plate that provides entry for bacteria and leads to a localized infection of the paronychial tissues of the hands (Figure 29). Symptoms may include inflammation, swelling, and/or scaling.



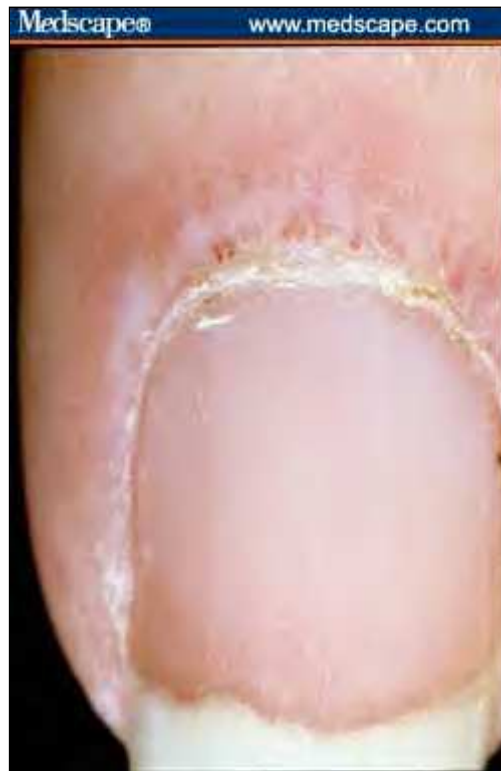

**Figure 29. Example chronic paronychia inflammation.**

#### **Periungal Telangiectasia**

Periungal telangiectasia is caused by dilated capillary loops and results in atrophy of the cuticle (Figure 30). It is strongly associated with collagen vascular disease, including the following:

- **Systemic lupus erythematosus;**
- **Dermatomyositis (especially with Gotton's papules over knuckles); and**
- **Scleroderma.**



**Figure 30. Example of periungal telangiectasia. Image courtesy of [www.dermnet.com](http://www.dermnet.com) Used with permission.**

#### **Mucus Cyst**

A mucous or myxoid cyst is a collection of degenerative collagen that can cause swelling and ridging of the nail above the cyst, forming a "gutter" (Figure 31).

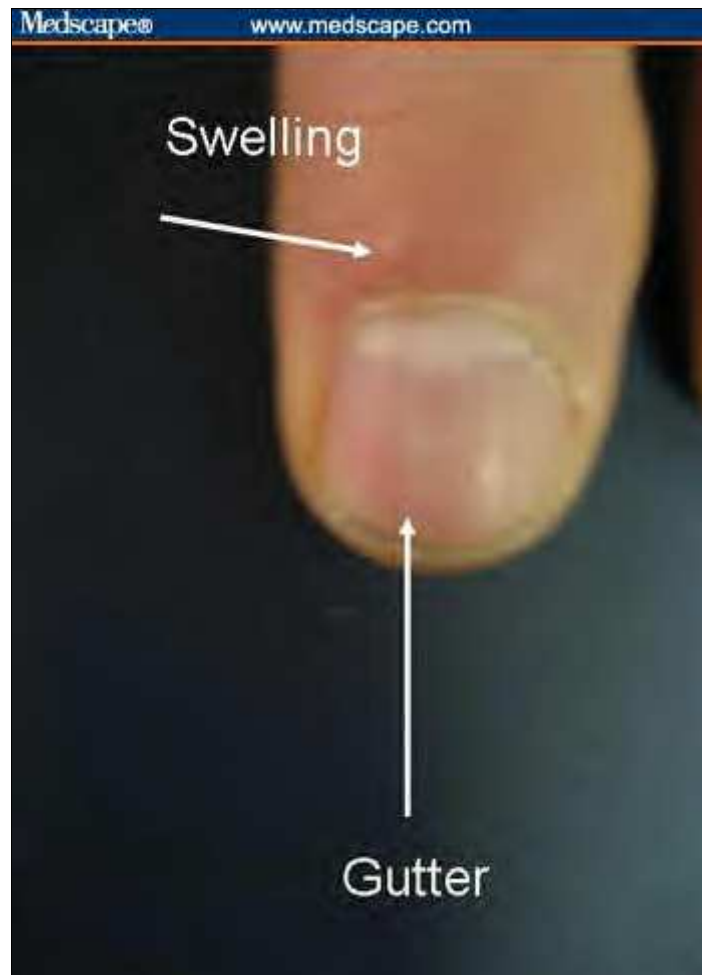


Figure 31. Example of a mucus cyst.


## Cases

The following are examples of patients in whom examining the fingernails may help identify their conditions.

Medscape® www.medscape.com

**78-year-old with diabetes mellitus, anemia, congestive heart failure, and peripheral vascular insufficiency**

- Red lunula can imply CHF
- Heller's line suggests peripheral vascular disease
- Ridging suggests diabetes or another endocrine condition
- Overall pallor suggests anemia



Slide 1. 78-year-old with multiple conditions.

Medscape® www.medscape.com

**84-year-old man with a painful ankle**

- Gout (tophi)
- CHF (red lunula)
- Anemia (pallor)
- Peripheral arterial disease (longitudinal red line)
- Chronic kidney disease (distal brown pigmentation)



Slide 2. 84-year-old man with a painful ankle.

Medscape® www.medscape.com

### 68-year-old man with esophageal cancer

- Extreme nail breaking implies resorption of distal digit
- In this case caused by PTH-like hormone produced by the malignancy
- Loss of lunula implies malnutrition or anemia



The image shows a close-up of a finger with a severely damaged nail. The nail is broken and crumbling, and the lunula (the white, crescent-shaped area at the base of the nail) is missing. Two white arrows point from the text to the broken nail and the missing lunula.

Slide 3. 68-year-old man with esophageal cancer.

Medscape® www.medscape.com

### 62-year-old woman with dermatomyositis

- Cuticular atrophy and periungal telangiectasias suggest collagen vascular disease
- Gotttron's papules over the knuckles imply dermatomyositis



The image shows a close-up of both hands of a woman. The skin over the knuckles is thickened and has a characteristic red, scaly appearance (Gotttron's papules). The skin around the nail beds is thin and fragile (cuticular atrophy), and there are small, dilated blood vessels visible around the nail beds (periungal telangiectasias). Two white arrows point from the text to the knuckles and the nail beds.

Image courtesy of www.dermis.com  
Used with permission

Note: Systemic lupus affecting the skin over the hands tends to spare the knuckles, while dermatomyositis tends to involve the knuckles

Slide 4. 62-year-old woman with dermatomyositis.

#### Acknowledgments

The author would like to thank the University of Virginia GME Office for funding support; Jim Thomas, MD, of www.Dermnet.com for permission to use images from their extensive dermatologic atlas; and the internal medicine residents at the University of Virginia for pre-testing and their helpful feedback.

---

## References

[ CLOSE WINDOW ]

## References

1. Baran R, Dawber RPR, De Berker D, Haneke E, Tosti A, eds. Baran & Dawber's Diseases of the Nails and Their Management. 3rd ed. London, UK: Blackwell Publishing; 2001.
2. Fawcett RS, Lindford S, Stulberg DL. Nail abnormalities: clues to systemic disease. Am Fam Physician. 2004;69:1417-1424. [Abstract](#)
3. Koler RA, Montemarano A. Dermatomyositis. Am Fam Physician. 2001;64:1565-1572. [Abstract](#)
4. Longshore TS, Tomecky KJ. Nail disease: signs for the internist. Cleveland Clinic Web site. Available at: <http://www.clevelandclinicmeded.com/medicalpubs/diseasemanagement/dermatology/naildisease/naildisease.htm> Accessed March 2, 2008.
5. Fleckman P, Lee J, Astion ML. Nail-Tutor: an image-based personal computer program that teaches the anatomy, patterns of pathology, and disorders of the nails. Dermatology Online Journal. 1997;3(2):2. Available at: <http://dermatology.cdlib.org/DOJvol3num2/nail/nail.html> Accessed March 2, 2008.
6. Rich P, Scher RK. An Atlas of Diseases of the Nail. Boca Raton, Fla: CRC Press; 2003. Encyclopedia of Visual Medicine Series; vol. 61.
7. Rockwell PG. Acute and chronic paronychia. Am Fam Physician. 2001;63:1113-1116. [Abstract](#)
8. Williams ME. Assessing the hands and wrists in elderly people. 2006. Medscape. Available at: <http://www.medscape.com/viewprogram/5202> Accessed March 2, 2008.
9. Williams ME. Geriatric Physical Diagnosis: A Guide to Observation and Assessment. Jefferson, NC: McFarland and Company, Inc. Publishers; 2007.

---

## Authors and Disclosures

As an organization accredited by the ACCME, Medscape, LLC requires everyone who is in a position to control the content of an education activity to disclose all relevant financial relationships with any commercial interest. The ACCME defines "relevant financial relationships" as financial relationships in any amount, occurring within the past 12 months, including financial relationships of a spouse or life partner, that could create a conflict of interest.

Medscape, LLC encourages Authors to identify investigational products or off-label uses of products regulated by the US Food and Drug Administration, at first mention and where appropriate in the content.

### Author

Mark E. Williams, MD

Ward K. Ensminger Distinguished Professor of Geriatric Medicine, University of Virginia, University of Virginia Healthsystem, Charlottesville, Virginia; Attending Physician, University of Virginia Healthsystem, Charlottesville, Virginia

Disclosure: Mark E. Williams, MD, has disclosed that he is a Co-Founder and Chief Scientist of BioMotion Analytics, LLC. Dr. Williams has also disclosed that he owns stock, stock options, or bonds for BioMotion Analytics, LLC.

### Editor

Carol Peckham

**Director, Editorial Development, Medscape, LLC**

**Disclosure: Carol Peckham has disclosed no relevant financial relationships.**

**Registration for CME credit, the post test and the evaluation must be completed online.**

**To access the activity Post Test and Evaluation link, please go to:**

**[http://www.medscape.com/viewprogram/8996\\_index](http://www.medscape.com/viewprogram/8996_index)**